

## Medial Patellar Luxation

### What is Medial Patellar Luxation (MPL)?

The patella is another name for the kneecap. Medial is another way of saying toward midline. Luxation is a term used to describe motion of a structure outside of its normal position or path. Therefore, the kneecap moves out of its normal position toward the body's midline. This condition is usually congenital (born with) and often hereditary (passed from parent to offspring). Mild luxations may not be evident until aggravated by minor trauma. As the patella is drawn outside of its normal position by forces placed upon it, the cartilage on the underside of the patella and on the end of the femur (thigh bone) becomes worn. In some cases, even the bone under the cartilage begins to wear and the patella more easily or permanently displaces. This abnormal wear causes inflammation, pain, and resultant lameness. Any breed can have a MPL, but it is commonly seen in Boston Terriers, Shih Tzus, and Cavalier King Charles Spaniels.

### Diagnosis

A diagnosis of patellar luxation is made by performing a thorough physical examination and reviewing x-rays. The luxations area graded I-IV based on severity.

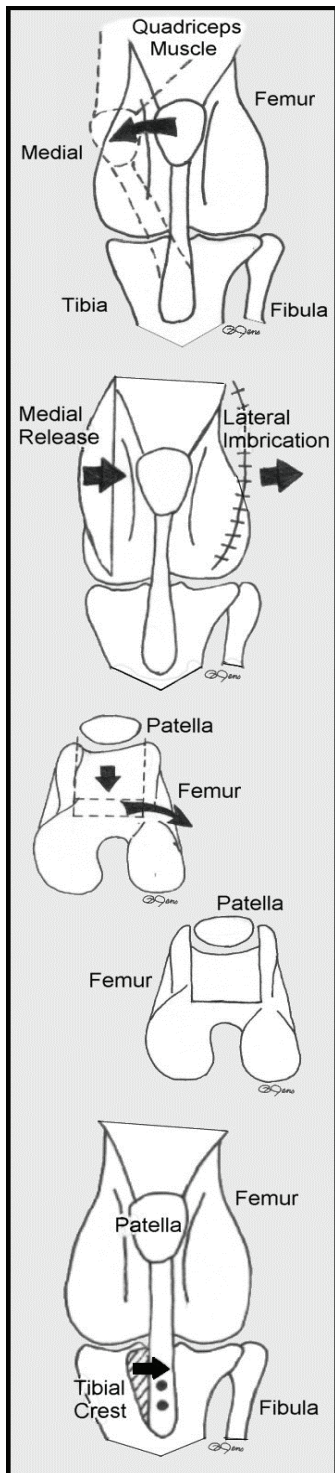
- Grade I - Patella can be manually luxated, but returns to the correct position when released. Typically it is in the correct position, but may occasionally luxate causing mild, intermittent lameness. Surgery is sometimes recommended.
- Grade II - Patella is easily luxated and moves in and out of position with motion of the knee. Intermittent pain and lameness are common. Surgery is typically recommended.
- Grade III - Patella is luxated most of the time but can be replaced manually. Pain and lameness are frequent or constant. Surgery is almost always recommended.
- Grade IV - Patella is out of the normal position all of the time and cannot be manually returned to its normal position. Abnormal gait and pain are usually constant. Surgery is usually indicated depending on the chronicity. Chronic grade IV luxations carry a much poorer prognosis than grades I-III.

### Treatment options

Correction of MPL is aimed at altering forces that pull the patella out of its normal position. Any or all of the following surgical techniques may be required for optimum long-term results.

#### Soft Tissue Repair

A releasing incision is made on the medial side of the joint to take away the pull from that side of the patella. A section of stretched tissue is removed from the lateral (away from midline) side of the joint and the fresh edges are sutured together to pull the patella laterally (imbrication).



### *Trochlear Block or Wedge Recession*

The femoral trochlear groove is the valley at the end of the femur that the patella glides within. It is bordered on the medial and lateral sides by ridges that help form the valley (groove). The recession deepens this groove so that the ridges are relatively higher and better able to maintain the patella in its proper alignment.

### *Tibial Crest Transposition*

The pull of the quadriceps muscle group dictates the movement of the patella within the trochlear groove. Most dogs with MPL will have medially displaced tibial crests. The displaced crest is surgically fractured, moved laterally into alignment with the quadriceps muscles and patella, which can then track normally within its deepened trochlear groove. The newly aligned crest is anchored with steel pins.